

# Concentrated Extracts of *Cassia fistula* Versus Intralesional Injection of Meglumine Antimoniate in Treatment of Acute Cutaneous Leishmaniasis

Fariba Jaffary<sup>1</sup>; Mohammad Ali Nilforoushzadeh<sup>2,1,\*</sup>; Shahram Moradi<sup>1</sup>; Roya Derakhshan<sup>1</sup>; Nazli Ansari<sup>1</sup>

<sup>1</sup>Skin Diseases and Leishmaniasis Research Center, Isfahan University of Medical Sciences, Isfahan, Iran

<sup>2</sup>Skin and Stem Cell Research Center, Tehran University of Medical Sciences, Tehran, Iran

\*Corresponding author: Mohammad Ali Nilforoushzadeh, Skin and Stem Cell Research Center, Tehran University of Medical Sciences, Tehran, Iran. Tel: +98-2122201710, Fax: +98-2122201710, E-mail: sdirc@mui.ac.ir

Received: November 13, 2013; Revised: January 24, 2014; Accepted: March 4, 2014

**Background:** Cutaneous leishmaniasis is an endemic disease in Iran. Although there are several treatment modalities for this disease, pentavalent antimonials are still considered as first line agents. There have been several reports concerning the effectiveness of *Cassia fistula* plant for leishmaniasis treatment.

**Objectives:** This study was designed to assess the effectiveness of concentrated boiled and hydroalcoholic extracts of *C. fistula* on leishmaniasis lesions in comparison with intralesional injection of meglumine antimoniate (MA).

**Patients and Methods:** In this randomized parallel clinical trial, 165 patients, 6-60 years old, with positive results of leishmaniasis smear tests were selected amongst the patients referred to the Skin Diseases and Leishmaniasis Research Center (SDLRC), Isfahan, Iran. They were randomly allocated to three groups for treatment with concentrated boiled extract of *C. fistula*, hydroalcoholic extract of *C. fistula*, and intralesional injection of MA. Patients were assessed at weeks one, two, three, four, and 16. Results of the treatment were reported as complete, partial, and no improvement.

**Results:** complete resolution of the lesions at week 16 was observed in 22 (40%), 20 (36.4%), and 36 (65.5%) patients, in those treated with concentrated boiled extract of *C. fistula*, hydroalcoholic extract of *C. fistula*, and intralesional injection of MA, respectively. The efficacy of intralesional injection of MA was significantly more than concentrated boiled extract of the *C. fistula* application ( $P=0.02$ ). In addition, the efficacy of intralesional injection of MA was significantly more than hydroalcoholic extract of the *C. fistula* application ( $P=0.005$ ). There was no significant difference between the efficacy of concentrated boiled extract and the hydroalcoholic extract of the *C. fistula* ( $P=0.61$ ).

**Conclusions:** Our study showed that almost 40% of the patients treated with *C. fistula* achieved complete resolution of the lesions. We recommend further evaluation of the effect of combined intralesional injection of MA and topical therapy with this plant, to assess the accelerating resolution of leishmaniasis lesions, and possibly decrease the applied dose of MA.

**Keywords:** Leishmaniasis, Cutaneous; Cassia Fistula; Meglumine Antimoniate

## 1. Background

Cutaneous leishmaniasis (CL) is still a significant health problem in Africa, Asia, and Latin America. According to the World Health Organization (WHO) report, 88 countries are afflicted with CL, and about 90% of the affected patients live in the following seven countries: Afghanistan, Algeria, Brazil, Iran, Peru, Saudi Arabia, and Syria (1). One of the most important foci of the CL in Iran is Isfahan (2). Numerous treatments with variable efficacies have been suggested for CL treatment. In the last few years, resistance to meglumine antimoniate (MA) has been increased (3, 4). Therefore, medications with mini-

mal side effects and optimum efficacy have been sought. Herbal drugs might have important roles in this respect. One of the plants used with variable success rates for CL treatment in southern parts of Iran is *Cassia fistula* (5). *C. fistula* has a wide variety of uses in folk medicine including treatment of diabetes, diarrhea, dysentery, fever, and uterine or menstrual disorders (6, 7). In addition, antiviral and hepato-protective activities have been previously reported (6). Acetone soluble fraction of this plant seeds has a bioactive glycoside with antimicrobial activity (7). *C. fistula* extract has been used for eradication of some

### Implication for health policy/practice/research/medical education:

*Cassia fistula* has shown significantly better wound closure and tissue regeneration in treated rats, compared with controls. This potential could be contributed to its efficacy in CL lesions. Our study showed that almost 40% of patients treated with this plant were completely cured. This finding offered clinical evidence on the folkloric use of *C. fistula* extracts for treatment of cutaneous leishmaniasis. We propose further evaluation of concurrent topical use of this plant with MA to hasten resolution of leishmaniasis ulcer and possibly decrease the dose of MA. A complete phytochemical analysis is required to identify the active ingredients with potential contribution in the observed activity of *C. fistula* for treatment of cutaneous leishmaniasis.

Copyright; ©2014, Skin and Stem Cell Research Center, published by Kowsar Corp. This is an open-access article distributed under the terms of the Creative Commons Attribution License, which permits unrestricted use, distribution, and reproduction in any medium, provided the original work is properly cited.

bacteria such as *Escherichia coli*, *Klebsiella*, *Staphylococcus aureus*, *Proteus vulgaris*, and *Pseudomonas aurogenosa* (8). Antioxidative effects were also reported for this extract, attributed to its phenolic and flavonoid compounds, and proanthocyanidin (9). Sartorelli et al. reported significant antileishmanial activity of *C. fistula* fruits hexane extracts on *Leishmania chagasi* (10). Mohebali et al. reported that 25% *C. fistula* extract could be effective in CL treatment (11).

## 2. Objectives

This study was designed to assess the effectiveness of concentrated boiled extract and hydroalcoholic extract of *C. fistula* on leishmaniasis lesions in comparison with intralesional injection of MA.

## 3. Materials and Methods

This study was a randomized parallel clinical trial for CL treatment, conducted in the Skin Diseases and Leishmaniasis Research Center (SDLRC), Isfahan, Iran. The institutional review boards of SDLRC approved the study protocol and all patients signed a written informed consent before entering the study. A total of 165 patients with confirmed CL, 6-60 years old, were recruited. CL was confirmed by examining the direct smear of the lesions. Demographic characteristics of the patients are shown in Table 1. Patients with the following criteria were excluded from this study:

- 1) The size of lesion was more than 3 cm.
- 2) The number of lesions was more than five.
- 3) The lesion duration was more than 12 weeks.
- 4) The lesion was located on the eyelid or less than 2 cm away from the eye.
- 5) Pregnant or lactating patients.

The patients were randomly allocated to three groups using table of random numbers. First group was treated with concentrated boiled extract of *C. fistula*, second group with its hydroalcoholic extract, and third group by intralesional injection of MA. The first applications of hydroalcoholic and concentrated boiled extracts of *C. fistula* were performed by the physicians. Thereafter, patients were instructed to apply the extract-soaked gauze on the lesions once a day until complete resolution of the lesion (complete epithelialization) or for a maximum duration of four weeks. The third group was treated by intralesional injection of MA (0.5-2 mL) twice a week until complete resolution of the lesion or for a maximum duration of four weeks. In all patients, size of the lesion was measured at weekly intervals for the first four executive weeks and at week 16, using glassy paper and millimeter paper for measuring the surface area of the lesion. At the end of the study, direct smear and culture were repeated. In the case of lesion progression or development of new lesions during the treatment, or patients' reluctance to continue the treatment, they were excluded from the study and their treatments were followed with other appropriate medications. Lesions were considered com-

pletely cured (improvement), if the patients achieved both clinical and parasitological resolutions (negative results of direct smear). Patients were considered resistant to the treatment, if no clinical changes were observed in the lesion or it was worsened. All patients who received at least one dose of the study treatment were included in the final analyses. All statistical tests were two-sided with significance ( $\alpha$ ) level of 0.05. The treatment groups were compared using chi-square and ANOVA tests. The data were analyzed using SPSS 10 software (SPSS Inc., Chicago, Illinois, USA).

### 3.1. Preparation of *Cassia fistula* Extracts

#### 3.1.1. Preparation of Hydroalcoholic Extract

Five hundred grams of *C. fistula* was powdered and mixed with 70% ethanol with ratio of 1:3, then placed in a percolator. After 48 hours, extraction was performed. The extract was then concentrated using distillation in vacuum condition.

#### 3.1.2. Preparation of Concentrated Boiled Extract

Five hundred grams of *C. fistula* was powdered and then mixed with water with ratio of 1:3, then boiled for 30 minutes and concentrated by distillation in vacuum condition.

## 4. Results

Demographic characteristics of the patients are shown in Table 1. Complete improvements were observed in 22 (40%), 20 (36.4%) and 36 (65.5%) patients in concentrated boiled extract of *C. fistula*, hydroalcoholic extract of *C. fistula*, and intralesional injection of MA, respectively. Efficacy of MA intralesional injection was significantly higher than concentrated boiled extract ( $P = 0.02$ ) and hydroalcoholic extract of the *C. fistula* ( $P = 0.005$ ) applications. There was no significant difference between application of concentrated boiled extract and hydroalcoholic extract of *C. fistula* regarding the efficacy ( $P = 0.61$ ). The mean resolution time was  $4.6 \pm 3.7$ ,  $4.9 \pm 3.8$ , and  $6.4 \pm 5.2$  weeks for concentrated boiled extract application, hydroalcoholic extract application, and intralesional injection of MA, respectively. There was no statistically significant difference among the groups regarding the resolution time ( $P = 0.27$ ). In the present study, 3 (5.5%) patients were in the concentrated boiled extract group and 2 (3.6%) patients in the other groups withdrew from the study due to the allergic reaction to the medications. There was no significant difference among these three groups in this regard ( $P = 0.61$ ). There was also no significant difference in the response rates among these three groups during the first four executive weeks of the treatment ( $P = 0.4$ ) (Table 2). Cumulative proportions of the improvement in these three groups during the study are presented in Figure 1.

**Table 1.** Demographic Characteristics of The Patients With Cutaneous Leishmaniasis, Treated With Meglumine Antimoniate and *Cassia fistula* Extracts (n = 55) <sup>a,b</sup>

	Concentrated Boiled Extract of <i>C. fistula</i>	Hydroalcoholic Extract of <i>C. fistula</i>	MA	P Value
<b>Gender</b>				0.15
Male	35 (63.6)	29 (52.7)	25 (45.5)	
Female	20 (36.4)	26 (47.3)	30 (54.5)	
<b>Age, y</b>	20.6 ± 12.4	19.8 ± 11.5	22.9 ± 13.6	0.4
<b>Location of lesions</b>				0.2
Foot	9 (16.4)	11 (20)	8 (14.5)	
Hand	25 (45.5)	23 (41.8)	24 (43.6)	
Trunk	5 (9.1)	6 (11)	5 (9.1)	
Head and neck	8 (14.5)	10 (18.2)	11 (20)	
Hand and foot	8 (14.5)	5 (9.1)	7 (12.7)	
<b>Number of lesions</b>	1.8 ± 1.13	1.72 ± 0.98	2.03 ± 1.07	0.3
<b>Kind of lesions</b>				0.02
Nodule	23 (41.8)	30 (54.5)	39 (70.9)	
Papule	17 (30.9)	11 (20)	5 (9.1)	
Papule and nodule	15 (27.3)	14 (25.5)	11 (20)	

<sup>a</sup> Data are presented in Mean ± SD or No. (%).

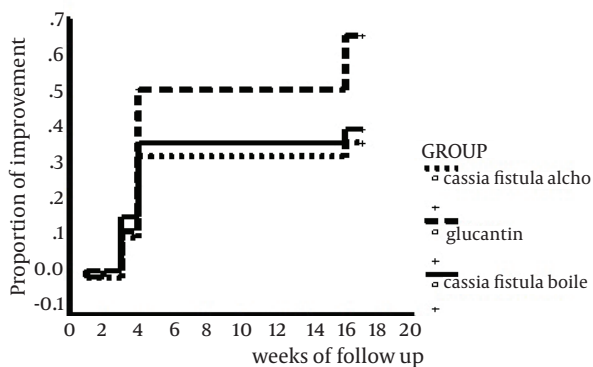
<sup>b</sup> Abbreviation: MA, Meglumine Antimoniate.

**Table 2.** Comparison of the Complete Cure Time Among Treatment Groups (Concentrated Boiled Extract of *Cassia fistula*, Hydroalcoholic Extract of *Cassia fistula*, and Meglumine Antimoniate)

	Concentrated Boiled Extract of <i>C. fistula</i> n	Hydroalcoholic Extract of <i>C. fistula</i> N	MA
<b>Week 1</b>	0	0	1
<b>Week 2</b>	1	0	0
<b>Week 3</b>	8	6	6
<b>Week 4</b>	11	12	21
<b>Week 16</b>	2	2 <sup>a</sup>	8
<b>Total number of patients with complete cure</b>	22 <sup>b</sup>	20 <sup>a</sup>	36

<sup>a</sup> P = 0.02 compared with MA.

<sup>b</sup> P = 0.005 compared with MA.



**Figure 1.** Comparison of Complete Cure Time of the Cutaneous Leishmaniasis Lesions Between Three Groups of Patients, Treated by Intralesional Injection of Meglumine Antimoniate and Topical Application of *Cassia fistula* Extracts

## 5. Discussion

Given many side effects of antimony compounds, there have been several trials for developing new alternative treatment options for CL. Among these trials, many treatments have been based on herbal remedies to find an effective topical modality for CL. Chauhan et al. reported antileishmanial effect of *C. fistula* hexane extract on *L. chagasi* promastigotes (12). Moreover, the *C. fistula* fruit gel has had an additive effect along with the intralesional MA injection in treating acute CL by increasing the resolution rate of the lesions (13). This study showed that intralesional MA injection was more effective than applying hydroalcoholic or concentrated boiled extracts of *C. fistula*. The healing time was shorter in treatment with hydroalcoholic as well as concentrated boiled extracts compared with intralesional MA injection. Although

even doses as high as 20000 g of this plant were shown to be nontoxic, there have been a few studies regarding the efficacy of this plant in CL treatment (14). *C. fistula* showed significantly better wound closure and tissue regeneration in treated rats compared with the controls (15). This evidence could be contributed to its efficacy in healing CL lesions. Our study showed that almost 40% of the patients treated with this plant achieved complete resolution of the lesions. This finding offers clinical evidence on the folkloric use of *C. fistula* extracts for CL treatment. We recommend further evaluation of concurrent topical use of this plant with MA injection, to hasten the resolution of leishmaniasis ulcer, and possibly decrease the dose of applied MA. A complete phytochemical analysis is required to identify the active ingredients, with potential contribution in the observed effectiveness of *C. fistula* in CL treatment.

### Acknowledgements

There was no acknowledgment.

### Authors' Contribution

All authors participated equally in this study.

### Financial Disclosure

There was no conflict of interest.

### Funding/Support

The study was self-funded.

### References

1. Desjeux P. The increase in risk factors for leishmaniasis worldwide. *Trans R Soc Trop Med Hyg.* 2001;**95**(3):239-43.
2. Ardehaly S, Azadeh B, Javadian E, Rezaei HR. *Leishmaniasis parasite and leishmaniasis.* Tehran: University publication center; 1984.
3. Groggl M, Thomason TN, Franke ED. Drug resistance in leishmaniasis: its implication in systemic chemotherapy of cutaneous and mucocutaneous disease. *Am J Trop Med Hyg.* 1992;**47**(1):117-26.
4. Croft SL. Monitoring drug resistance in leishmaniasis. *Trop Med Int Health.* 2001;**6**(11):899-905.
5. Saeedi A. *Parasitic diseases in Iran.* 4th ed Tehran: Roozbehan publication; 1984.
6. Akanmu MA, Iwalewa EO, Elujoba AA, Adelusola KA. Toxicity potentials of *Cassia fistula* fruits as laxative with reference to Sena. *Afr J Biomed Res.* 2004;**7**(1):23-6.
7. Yadava RN, Verma V. A new biologically active flavone glycoside from the seeds of *Cassia fistula* (Linn.). *J Asian Nat Prod Res.* 2003;**5**(1):57-61.
8. Perumal Samy R, Ignacimuthu S, Sen A. Screening of 34 Indian medicinal plants for antibacterial properties. *J Ethnopharmacol.* 1998;**62**(2):173-81.
9. Luximon-Ramma A, Bahorun T, Soobrattee MA, Aruoma OI. Antioxidant activities of phenolic, proanthocyanidin, and flavonoid components in extracts of *Cassia fistula*. *J Agric Food Chem.* 2002;**50**(18):5042-7.
10. Sartorelli P, Andrade SP, Melhem MS, Prado FO, Tempone AG. Isolation of antileishmanial sterol from the fruits of *Cassia fistula* using bioguided fractionation. *Phytother Res.* 2007;**21**(7):644-7.
11. Mohebbali M, Chenari A, Nazari MR. Effect of *Cassia fistula* on leishmania major ulcers in small laboratory with mice. *Pajouhandeh Q Res J.* 1999;**1**:14-9.
12. Chauhan N, Bairwa R, Sharma K, Chauhan N. Review on *Cassia fistula*. *IJRAP.* 2011;**12**(2):426-30.
13. Jaffary F, Nilforoushzadeh M.A, Ansari N, Rahimi M. Treatment of cutaneous leishmaniasis: *Cassia fistula* fruit gelintralesionalglucantime Vs. placebo gel- intralesionalglucantime combination. *Tehran Univ Med J.* 2010:705-11.
14. Ilavarasan R, Mallika M, Venkataraman S. Anti-inflammatory and antioxidant activities of *Cassia fistula* Linn bark extracts. *Afr J Trad.* 2005;**2**(1):70-85.
15. Senthil Kumar M, Sripriya R, Vijaya Raghavan H, Sehgal PK. Wound healing potential of *Cassia fistula* on infected albino rat model. *J Surg Res.* 2006;**131**(2):283-9.